

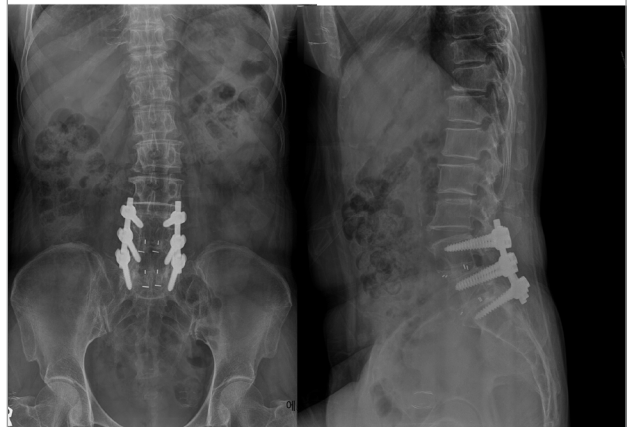Session V

Abdominal pain after OLIF

권흠대
에스포항병원

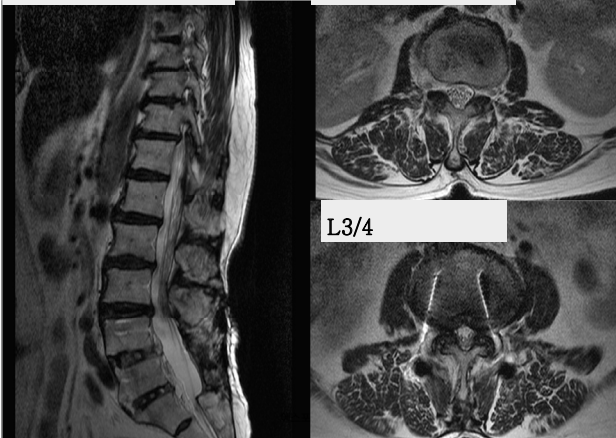F/75
left buttock pain; NIC; back pain
10년
허리가 굽어진다. 바로 못 앉는다.
N/E; kyphotic
SLRT (-/-)
Motor ok
Sensory ok
DTR'S AJ (2/2) KJ (2/2)
Bending Limitation (-)
Direct tenderness (-)
Patrick's sign (-/-)
FNST (-/-)
LOM limitation (++, flexion/extension)
2006년 안세병원에서 허리수술
위암수술
2016년 2월; left knee; TKR; ; 10년전 rt knee; TKR

2013



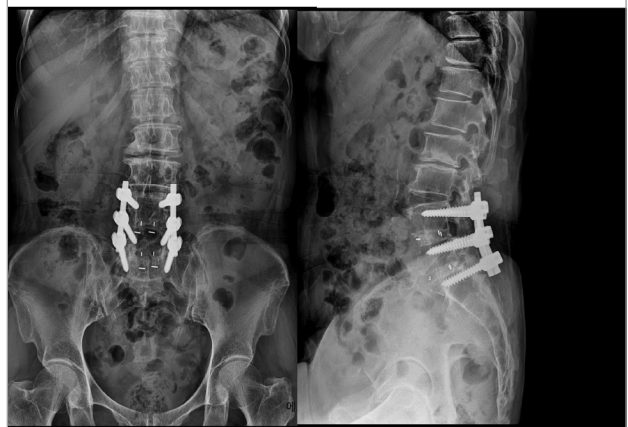
2013

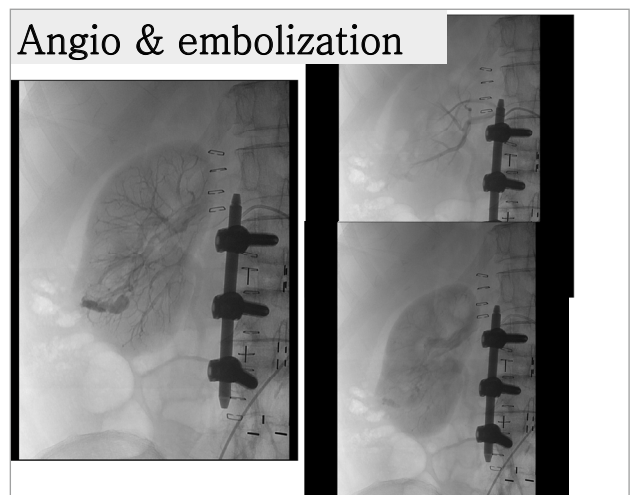
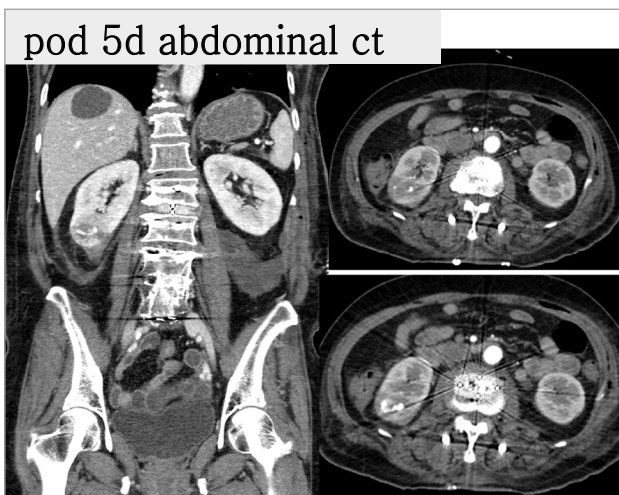
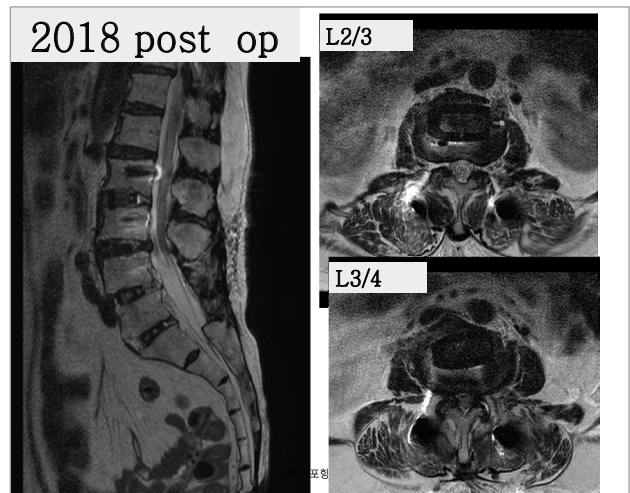
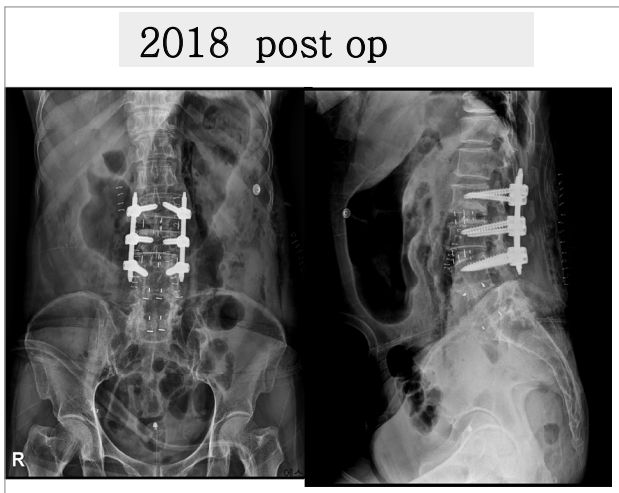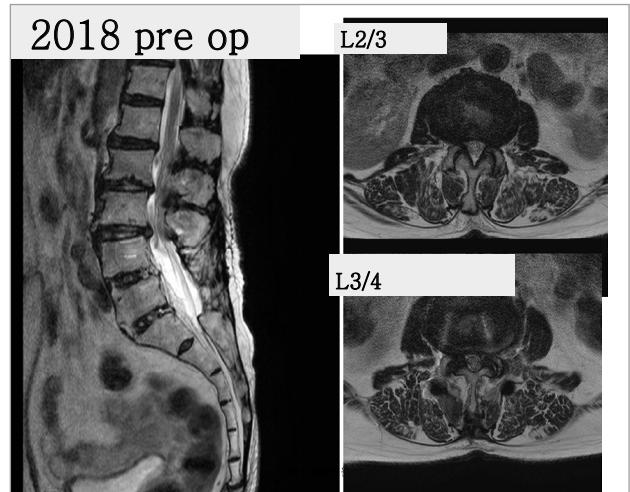
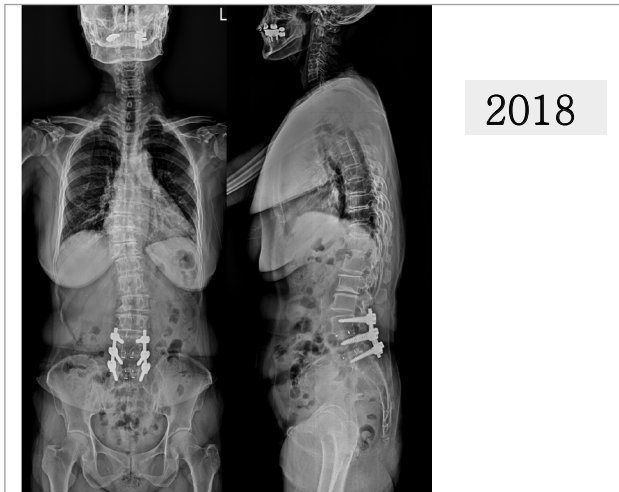
L2/3



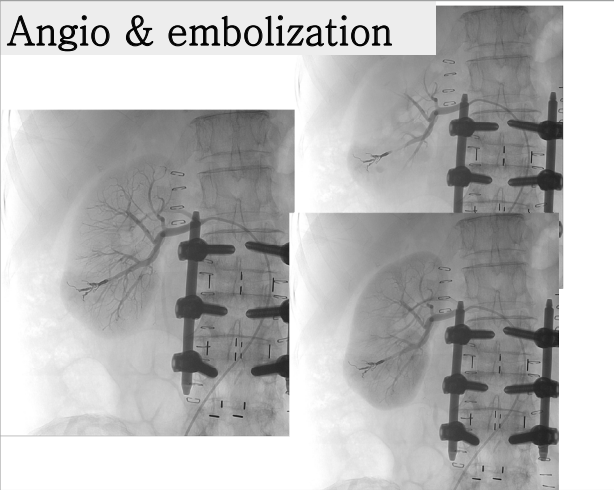
L3/4

2018

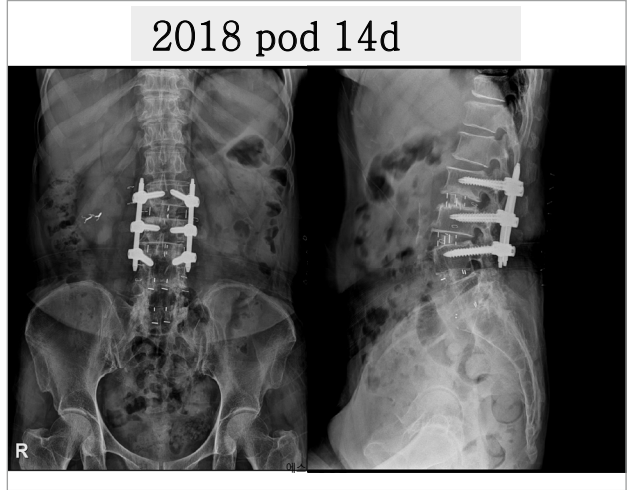



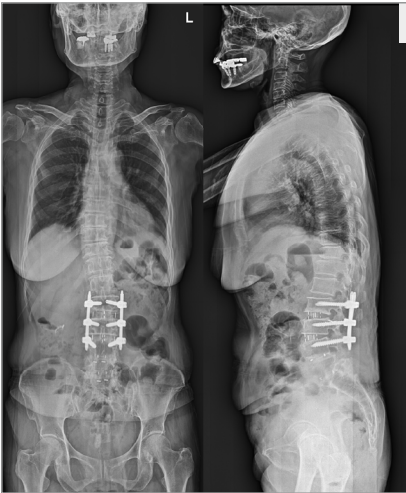
Angio & embolization



2018 pod 14d



2018 pod 14d



2015. 9.1 이후

