

Session IV

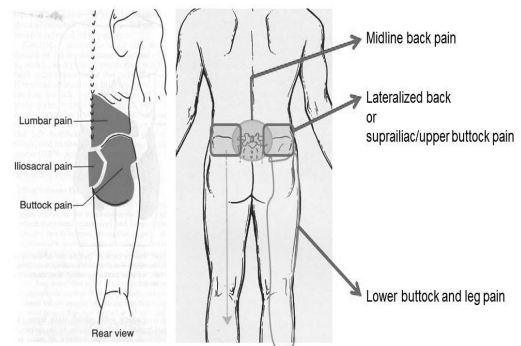
# Persistent Pain after Decompressive Laminectomy

진용준  
인제의대

## Persistent pain types

- Back pain (midline, ipsilateral suprailiac, upper buttock)
- Leg pain (lower buttock, thigh, calf, dorsum of foot, sole, BT)
- Phase (acute, subacute, chronic)

## Classification by pain distribution



## Surgical options

### ▪ Laminectomy only (partial or total)

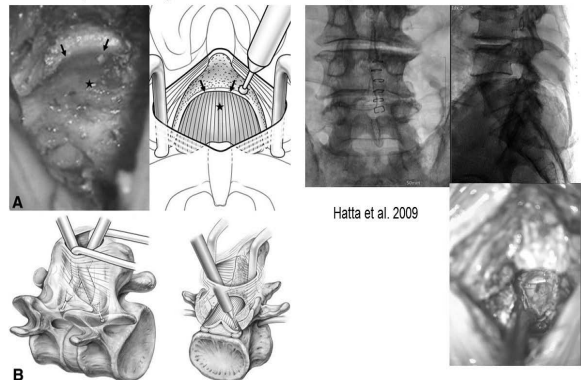
merit : direct decompression, preservation of less movable disc  
demerit : exposure of synovial space (facet joint pain, synovial cyst)  
increased instability (facet joint pain, disc protrusion, synovial cyst)

### ▪ Laminectomy & fusion (PLIF/TLIF/DLIF/XLIF/OLIF)

merit : indirect decompression, preserved posterior element, lumbar lordosis (DLIF, XLIF, OLIF)  
direct decompression, lumbar lordosis (PLIF, TLIF)

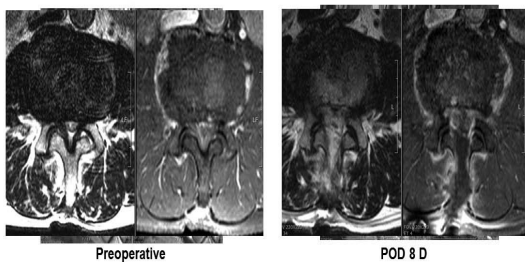
demerit : adjacent segment pathology/non-union/subsidence/screw failure/  
pain related to instrumentation (common problems), myofascial pain syndrome  
lumbosacral plexus injury (DLIF, XLIF), muscle atrophy (PLIF, TLIF)

## Muscle preserving interlaminar decompression



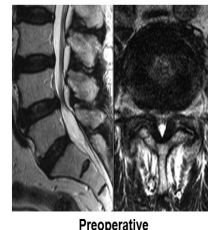
**송00 1773179 M63 EDH asymptomatic**

- both symmetric buttock and posterior thigh pain VAS 7, not calf pain,
- Extension/standing : aggravation of pain, Flexion : relieving
- POD 8D : MRI asymptomatic EDH

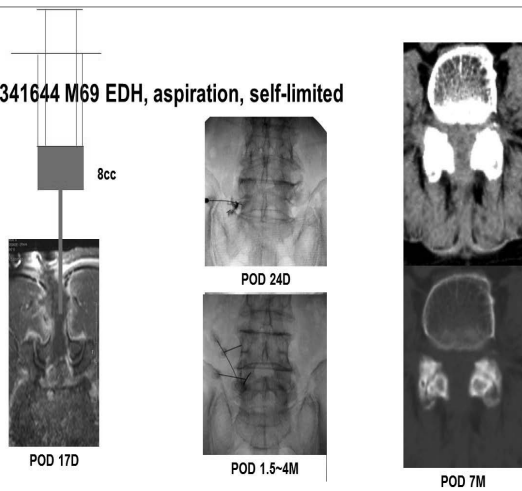


**김00 1341644 M69 EDH, aspiration, self-limited**

- Within 1wk : residual lower leg foot paresthesia, buttock and thigh improved dexamethazone ivs
- POD 10D : residual lateral calf, foot paresthesia sustained
- POD 17D : wound bulging, hematoma aspiration at OPD
- POD 24D : L5-S1 TF SR ESI for lower leg Sx
- POD 48D : back pain→MBB
- POD 4M : back pain→MBB
- POD 7M F/U CT : all Sx resolved

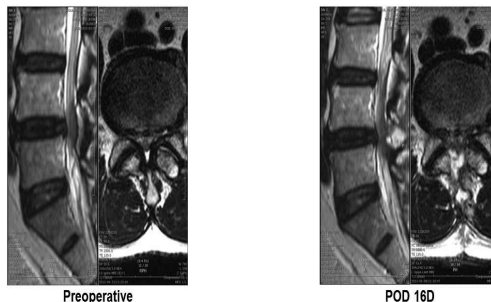


**김00 1341644 M69 EDH, aspiration, self-limited**



**변00 1638019 M62 EDH 16D, revision hematoma evacuation**

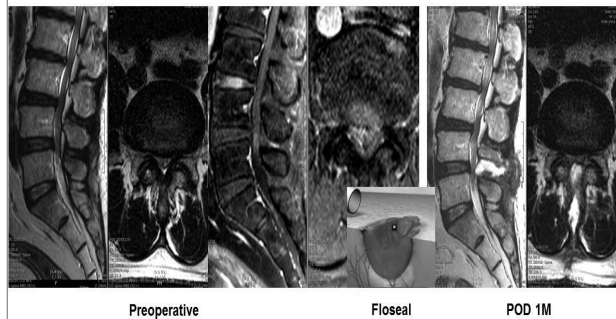
- Both(Rt>Lt) posterior leg pain, NIC(+), standing/walking pain, stooping OK



**박00 1155843 M54 EDH 1M, revision hematoma evacuation**

- 3MA Both buttock, posterior thigh, LBP at rest VAS 3, standing, walking VAS 8
- 2015/3/30 MRI : L4-5>L3-4 central stenosis but only L4-5 cauda equina CE(+)
- 2015/4/1 L4 dome laminoplasty with Floseal
- 2015/4/10 VAS 0
- 2015/5/1 sudden both buttock, posterior leg pain, scrotal pain, alternating pain
- 2015/5/11 MR F/U : EDH organization and Floseal mass effect  
revision hematoma evacuation 직후 partial improvement
- 2015/5/12 VAS 3 lying pain disappeared 다리 펴고 잔다. standing, walking pain
- 2015/6/1 Lt symptom remained, L5-S1 Bo TF SR ESI
- 2015/6/16 500m-1km 걸어도 된다.
- 2015/6/30 1km 이상 걸어도 된다. 발바닥에 약간 저림 오지만 OK.

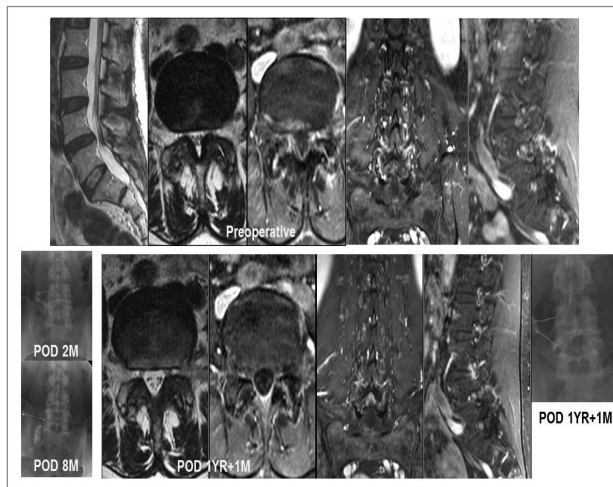
**박00 1155843 M54 EDH 1M, revision hematoma evacuation**





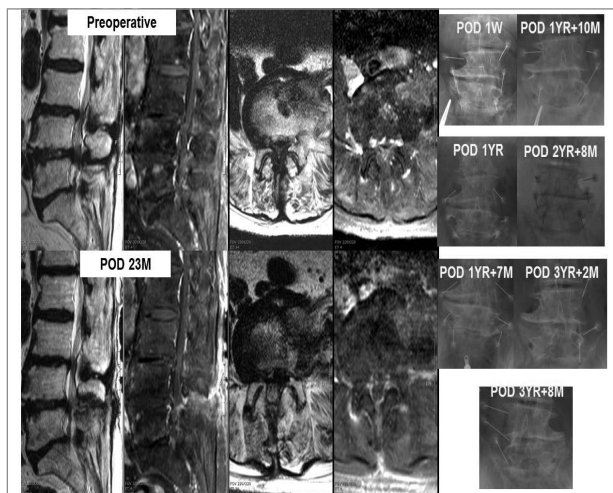
**염00 1379576 F62 facet joint pain 2M intermittent, MBB**

- 1YA Lt suprailiac, buttock(dominant) posterior thigh pain calf paresthesia
- 3MA Rt thigh, calf pain
- 2016/10/31 MR L4-5 SPL LS IRCE(-) DVCE(+) PVCE(+) Bo L5 traversing root L4-5 Bo(Lt>Rt) facet joint synovium CE, capsule CE
- 2016/12/16 L4 dome laminoplasty 80% improved
- 2017/2/16 leg pain(-), but residual Lt iliac crest 주변부 통증, motion pain, dynamic mechanical pain으로 facet instability
- 2017/2/20 MBB 90% improved
- 2017/8/7 Lt suprailiac + upper buttock pain, L5-S1 Lt TF SR ES1 : no effect
- 2018/1/16 MR F/U L4-5 Bo(Lt>Rt) facet joint synovium CE, capsule CE
- 2018/1/18 MBB 90% improved



**장00 1144940 F78 facet joint pain 1W chronic, repetitive MBB**

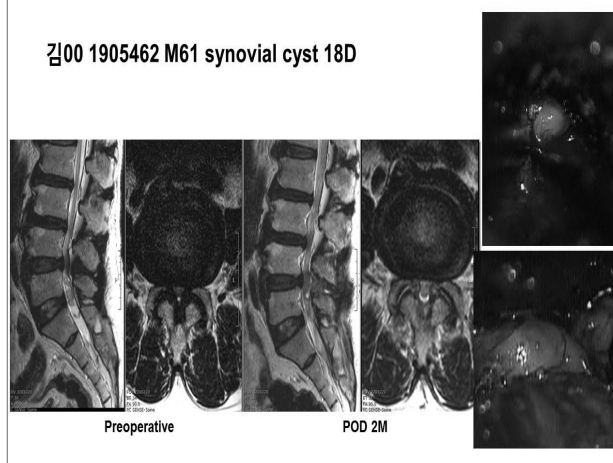
- 2WA Rt buttock and leg pain, 일어나서 걷지 못한다.
- 2014/4/8 MR : L4-5 CS LS severe, L3-4 CS, L5-S1 Rt foraminal stenosis, L1-2 CS Rt SA HIVD
- 2014/4/8 L4 dome laminoplasty
- 2014/4/16 back pain→ MBB #1, 6개월간 OK.
- 2015/4/15 back pain만 남았다→ MBB #2
- 2015/11/9 MBB #3
- 2016/2/23 MR F/U synovial cyst의한 restenosis 의심됨, no leg pain
- 2016/2/29 MBB-->2016/12/14 MBB-->2017/6/13 MBB→2017/12/18 MBB



**김00 1905462 M61 synovial cyst 18D**

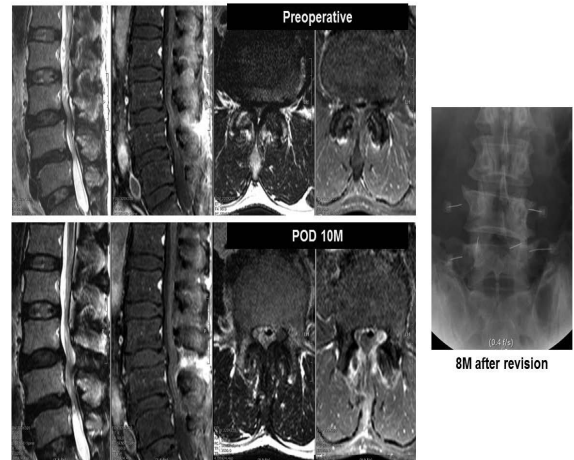
- 3YA Both(Rt>Lt) buttock to ankle, tingling sense
- 2017/6/24 MR L4-5 CS
- 2017/7/1 local clinic caudal block 2회 호전 없어서
- 2017/9/27 MR L4-5 CS DVCE(+) IRCE(-) PVCE(-) RNR(-) NRSS(+)
- 2017/9/29 L4 dome laminoplasty
- 2017/10/17 acute back pain during extension developed
- 2017/10/18 MBB, 1달간 OK
- 2017/11/21 both(Rt>Lt) posterior thigh calf pain during walking, rising from sitting extension pain, flexion relieved→ F/U MRI L4-5 Rt>Lt synovial cyst
- 2017/12/29 wound revision, synovial cyst removal
- 2018/1/6 much improved

**김00 1905462 M61 synovial cyst 18D**



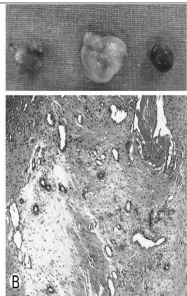
**김00 1848968 M56 persistent lower leg Sx, synovial cyst 5M**

- NIC(+) KE 4+/4+ ADF 4-/4 Rt>Lt leg paresthesia, walking difficulty
- 2015/10/20 MR L3-4>L4-5 CS LS, Rt L4, L5 PVCE, Rt DVCE
- 2015/11/4 L3 dome laminoplasty
- 2015/11/17 KE/ADF weakness improved Rt>Lt lower leg paresthesia는 여전한 듯
- 2015/12/14 ankle weakness improved but both calf paresthesia remained
- 2016/4/19 Lt posterior thigh calf pain(2DA), Rt leg Sx improved
- 2016/4/25 L3-4 Lt TF IR ESI #1, 40% 2016/6/13 L3-4 Lt TF IR ESI #2, no effect
- 2016/8/30 MR L3-4 Lt synovial cyst with L4 traversing root compression
- 2017/2/27 Lt lateral calf pain aggravation
- 2017/4/19 revision, synovial cyst removal, L4 exploratory dome laminoplasty
- 2017/8/29 leg Sx improved→2017/12/14 LBP, MBB→2018/1/11 OK



**Postlaminectomy synovial cyst formation**

- 8%, all lumbar
- More frequent for stenosis than other diagnoses
- L4-5 : most commonly affected
- Related to the creation of iatrogenic instability
- Mechanical property of LF: instrumental in stability for high strain conditions
- During laminectomy, ligamentum excision and exposing the medial aspect of the joint cause the egress of synovium epidurally, and the subsequent formation of the cyst.



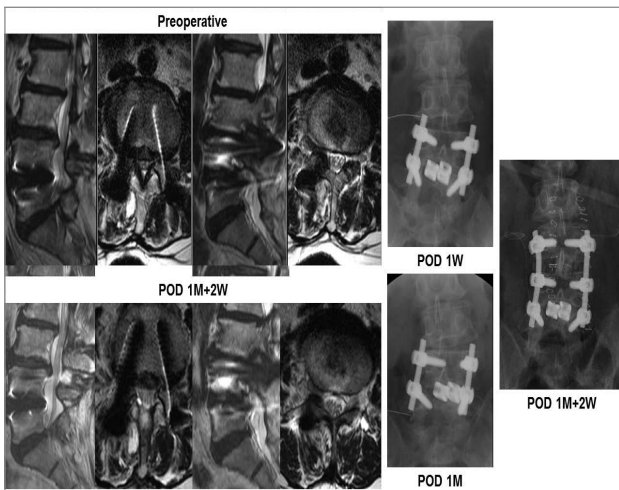
Walcot et al. Journal of Clinical Neuroscience 19 (2012) 252-254, Cho et al. Korean J Spine 13(3):157-159, 2016

**서00 1751478 F59 foraminal stenosis aggravation 1.5M later**

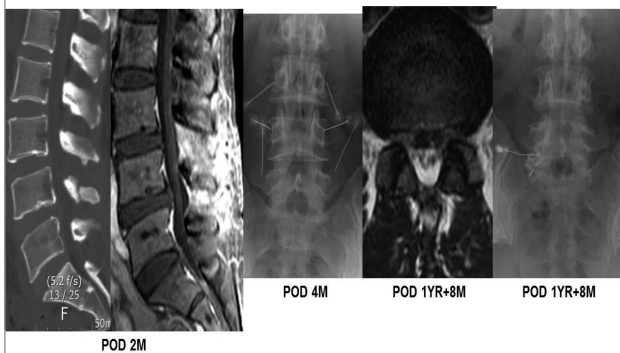
- Rt lateral calf pain : 2-3M after L4-5 PLIF with cage without PSF
- 2012/2/7 L4-5 Rt foraminal stenosis, scoliotic→L4-5 PSF
- 2014/8/6 both leg Sx, MR L3-4 central stenosis, Rt foraminal stenosis, scoliotic
- 2014/8/10 L3 dome laminoplasty but Rt lower leg Sx remained
- 2014/8/18 L3-4 Rt TF IR ESI, no effect
- 2014/9/4 L5-S1 Rt TF SR ESI, no effect
- 2014/9/23 MR L3-4 central decompression(+) with mild EDH < foraminal stenosis
- 2014/9/24 L3-4-5 PLIF
- 2015/6/29 L1,L2,L3 MBB
- 2017/7/25 Mx only, L2-3 scoliotic, Rt disc collapsed

**우00 1763838 F43 spinous process fx 2M, facet joint pain 4M, protrusion on the index level 20M**

- NIC(-), both buttock and posterior thigh pain, 의자에 앉아 오래 있어야
- 2014/10/20 MR L3-4, L4-5 CS LS cauda equina CE, L4-5 Lt traversing root CE
- 2014/11/5 L3,L4 dome laminoplasty
- 2015/1/5 spinous process fx pain + Rt anterior thigh pain only
- 2015/4/16 L4 spinous process fx부위 통증만 있다.
- 2015/6/4 3MA 허리 통증, buttock and posterior thigh pain
- 2015/6/10 MBB 50% improved→ no back pain
- 2016/8/9 1MA Rt LBP buttock lateral calf(dominant) pain
- 2016/8/25 L4-5 Rt SA protrusion, L5-S1 Rt TF SR ESI
- 2016/9/26 Rt buttock & lateral calf pain disappeared



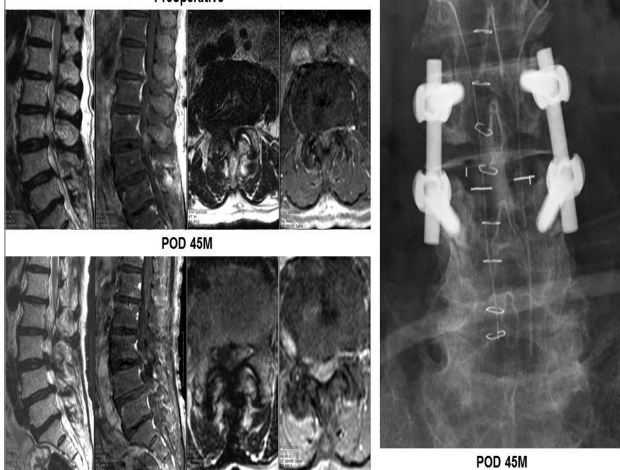
우00 1763838 F43 spinous process fx 2M, facet joint pain 4M, protrusion on the index level 20M



김00 1778740 F67 extrusion on the index level 45M later

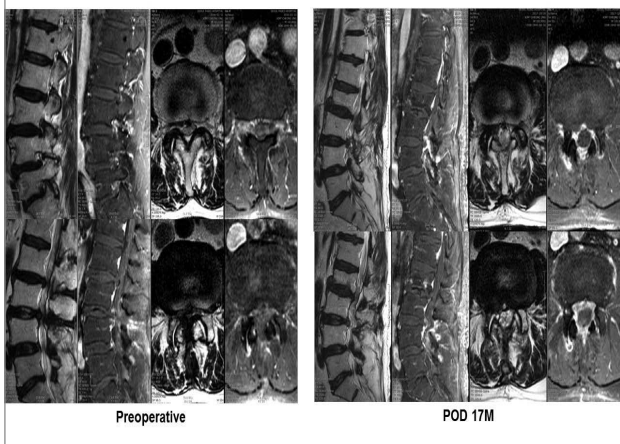
- NIC(+), 버스 한 정거, sitting OK, standing walking pain, VAS 6
- 2013/1/3 L4 dome laminoplasty 30% 호전
- 2013/1/11 MR L3-4 cauda equina CE 확인
- 2013/2/7 L3 dome laminoplasty
- 2013/2/26 No pain
- 2016/11/28 1YA both buttock posterior thigh pain  
MR L3-4 central to Rt SA extrusion, severe central stenosis
- 2016/12/9 L3-4 TLIF
- 2017/2/23 much improved, 허리에서 염발음(+)

Preoperative

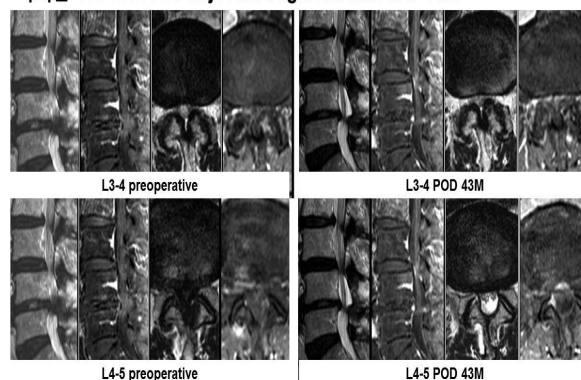


김00 1813005 M75 contralateral back & leg pain 10D  
contralateral extrusion on the index level 17M

- 1MA both sole hypesthesia, Lt LBP, buttock, thigh, upper lateral calf pain, Rt upper buttock intermittent pain
- 2016/2/15 MR L3-4 CS severe, LS, Rt FS > L2-3 CS
- 2016/5/13 L3 dome laminoplasty
- 2016/5/26 Lt side Sx VAS 0, 3DA Rt anterior thigh pain, back pain  
L3-4 Rt TF IR ESI, MBB L2, L3, 4 Rt anterior thigh pain disappeared
- 2016/6/30 Rt buttock leg pain (-), Rt LBP sometimes
- 2016/7/4 MBB L4, L5, S1 effect(-)
- 2016/8/11 L4-5 Rt TF IR ESI, 직후 much improved but recurred
- 2017/10/30 Rt buttock/lateral thigh pain, MR L3-4 Rt F SA extrusion, L3-4 Rt TF ESI
- 2017/12/26 50% improved, walking 가능함 TLIF 연기

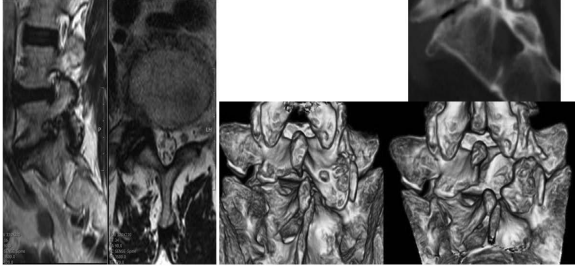


박희순 1794544 F76 adjacent segment stenosis 43M



**강동삼 1430157 M70 isthmus fx**

- Rt suprailiac pain
- L5-S1 Rt facet arthritis with foraminal stenosis
- POD 44M : 30% residual back pain, intermittent MBB



**Conclusions**

- Back pain : facet joint pain (newly developed or pre-existing)  
protrusion or extrusion  
spinous process fx, rarely isthmus fx
- Leg pain : EDH (m/c asymptomatic or self-limited, subacute, organizing hematoma)  
protrusion or extrusion  
synovial cyst (m/c asymptomatic or self-limited)  
pre-existing foraminal stenosis (inappropriate diagnosis)
- Neuropathic pain : included depending on the severity and duration of pain  
necessary for the explanation of residual discomfort